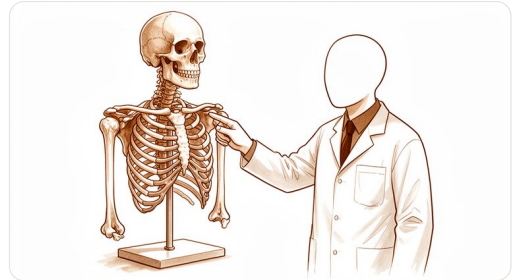


# How your wrist works



Posterior view of the wrist ligaments (Gray's Anatomy): a dense network of short ligaments binds the eight carpal bones to one another and connects them to the radius, ulna and hand.

Kieran Hirpara 4.0

## The bones

Your wrist is the busy bridge between your forearm and your hand. It handles the complex forces of lifting, typing, and pushing. Think of it as a sophisticated hinge that also needs to twist.

Three bones make up the main structure. Two long bones run down your forearm. The radius sits on the thumb side. The ulna sits on the pinky side. These bones meet the eight small wrist bones, called carpals.

You can feel the end of the ulna on the pinky side of your wrist. It sticks out like a small bony knob. This is the ulnar head. The radius is wider and sits on the thumb side. You cannot feel its end as clearly.

The carpals form two rows. They look like a cluster of small pebbles. You can feel them if you press gently along the base of your palm. These bones allow your wrist to bend and tilt. They also absorb shock when you land on your hands.

## The joints and how they move

Your wrist relies on several joints working together. Each joint has a specific shape and job.

The main wrist joint is the radiocarpal joint. It is a condyloid joint. This means it bends forward and backward. It also tilts side to side toward the thumb or pinky. However, it does not rotate like a ball in a socket. Imagine a pebble resting in a shallow spoon. It can roll in many directions but stays put.

The thumb base has a special joint. It is the carpometacarpal joint. This is a saddle joint. Its shape allows your thumb to cross your palm. This movement lets you touch your fingertips. It is essential for gripping and pinching.

The bones in your forearm rotate around each other. This happens at the proximal and distal radioulnar joints. These are pivot joints. They allow your palm to face up or down. Turning a doorknob uses this rotation. It happens evenly along the forearm, not just at the elbow.

The small bones in the wrist slide past each other. These are plane joints. They allow tiny gliding movements. This adds flexibility to your wrist motion.

## The muscles, tendons and ligaments

---

Muscles in your forearm control your wrist and fingers. They do not sit in your hand. Instead, they sit in your forearm. Their long tendons stretch down to your hand.

Tendons are tough cords that connect muscle to bone. You can feel these tendons on the front and back of your wrist. When you make a fist, you can see them stand out. They pull your fingers and wrist into position.

Ligaments are strong bands of tissue. They connect bone to bone. They keep your wrist joints stable. The volar radiocarpal ligament is a key stabilizer. It prevents your wrist from bending too far back. Another ligament, the scapholunate ligament, holds two small wrist bones together. If this tears, your wrist may feel unstable.

Think of your tendons as ropes. The muscles are the engines pulling those ropes. The ligaments are the anchors holding the system together. Without strong ligaments, the bones would slip out of place.

## The nerves

---

Nerves carry signals between your brain and your hand. They control movement and sensation. Three main nerves pass through the wrist area.

The median nerve runs through the carpal tunnel. This is a narrow passage on the palm side of your wrist. It provides sensation to your thumb, index, and middle fingers. It also controls some small muscles in the base of your thumb. Compression here causes carpal tunnel syndrome.

The ulnar nerve runs on the pinky side of your wrist. It passes through a groove near the ulnar head. It provides sensation to your pinky and half of your ring finger. It controls many small muscles in your hand. These muscles help with fine finger movements.

The radial nerve runs on the back of your wrist. It provides sensation to the back of your hand. It also helps extend your wrist and fingers. If this nerve is injured, you might have trouble lifting your wrist up.

Knowing which nerve does what helps explain your symptoms. Numbness in specific fingers often points to a specific nerve. This helps your surgeon locate the problem quickly.